

# Articular Cartilage Paste Grafting to Full-Thickness Articular Cartilage Knee Joint Lesions: A 2- to 12-Year Follow-up

Kevin R. Stone, M.D., Ann W. Walgenbach, R.N.N.P., M.S.N., Abhi Freyer, Thomas J. Turek, and Donald P. Speer, M.D.

---

**Purpose:** To prospectively assess clinical outcomes and regeneration of osteoarthritic cartilage lesions treated with an articular cartilage paste grafting technique. **Type of Study:** Prospective, longitudinal case series. **Methods:** We treated 125 patients (136 procedures; 34% female, 66% male; mean age, 46 years; range, 17 to 73 years) with an Outerbridge classification of grade IV lesions with an articular cartilage paste graft. Clinical data were recorded 2 to 12 years from surgery, with 20 of 145 patients lost to follow-up over 12 years (13.7%). Clinical outcomes were captured annually with validated Western Ontario and McMaster Universities Arthritis Index (WOMAC), International Knee Documentation Committee (IKDC), and Tegner subjective questionnaires. Regenerated cartilage biopsy specimens were obtained at second-look arthroscopy from 66 patients and evaluated as to quality and quantity of defect fill by a blinded, independent histopathology reviewer. **Results:** Preoperative versus postoperative validated pain, functioning, and activity measures improved significantly ( $P < .001$ ). Clinically, 18 of the 125 patients were considered failures (14.4%), with 10 patients undergoing subsequent joint arthroplasty and 8 who reported worse pain after surgery. Regional histologic variation occurred. Forty-two of 66 biopsy specimens (63.6%) showed strong and consistent evidence of replacement of their articular surface, and 18 of 66 biopsy specimens (27.3%) showed development of areas of cartilage. **Conclusions:** Paste grafting is a low-cost, 1-stage arthroscopic treatment for patients with Outerbridge classification grade IV arthritic chondral lesions. The procedure offers excellent, long-lasting, pain relief, restored functioning, and possibility of tissue regeneration for patients with painful chondral lesions in both arthritic and traumatically injured knees. **Level of Evidence:** Level IV, case series. **Key Words:** Cartilage—Chondral lesions—Arthritis—Paste grafting—Clinical outcomes—Articular cartilage repair.

---

Untreated articular cartilage lesions have a limited ability to heal and may promote degenerative changes in the knee.<sup>1,2</sup> Damage to the structure and function of the articular cartilage leads to pain, loss of range of motion, crepitation, swelling, and eventually deformity. Surgical efforts to restore articular cartilage involve a wide variety of surgical procedures. These include debridement procedures, such as chon-

dral shaving; marrow stimulation procedures, such as abrasion arthroplasty; penetration of the subchondral bone by drilling or microfracture; cartilage resurfacing and regrowth procedures, such as autologous osteochondral transplantation; the use of an artificial matrix, periosteum transplantation, and autologous chondrocyte transplantation, among others.<sup>1-23</sup> Although recent prospectively controlled, randomized, comparative studies of autologous chondrocyte implantation, microfracture, and osteochondral plugs have reported promising clinical results, none has shown the consistent formation of normal articular cartilage and none has been indicated for arthritic knees.<sup>24-26</sup> To restore lost function, alleviate pain, and prevent degenerative changes within the knee, the ideal cartilage treatment should be minimally invasive and result in hyaline cartilage regrowth in the area of the defect, fully

---

From The Stone Research Foundation (K.R.S., A.W.W., A.F., T.J.T.), San Francisco, California; and the University of Arizona College of Medicine (D.P.S.), Tucson, Arizona.

Address correspondence and reprint requests to Kevin R. Stone, M.D., The Stone Research Foundation, 3727 Buchanan St, San Francisco, CA 94123, U.S.A. E-mail: kstonemd@stoneclinic.com

© 2006 by the Arthroscopy Association of North America

0749-8063/06/2203-05-272\$32.00/0

doi:10.1016/j.arthro.2005.12.051

integrated with native bone and surrounding cartilage. Few surgical options are indicated for large lesions, patients with severe arthrosis, or for older patients.<sup>27-29</sup>

The paste grafting technique, previously reported by Stone and Walgenbach,<sup>30,31</sup> is an arthroscopic procedure using historical methods of lavage, debridement, and subchondral fracture to stimulate autologous mesenchymal stem cell proliferation, differentiation, and growth factor release. To present a 3-dimensional autogenous cartilage matrix with chondrocytes to large defects, an osteocartilaginous paste graft is harvested from the intercondylar notch, crushed into a paste, and impacted into the fractured chondral defect. The combined morselized paste of articular cartilage and subchondral bone is hypothesized to augment the mesenchymal stem cell supply from vascularized subchondral marrow access, and may present the necessary cellular signals and conductive matrix to produce an appropriate repair tissue. Animal studies have further suggested the superiority of paste grafting to controls and histologic regeneration of cartilage repair surfaces in defects both in arthritic knees and acute trauma.<sup>32,33</sup> The technical feasibility of the placement and persistence of the osteocartilaginous paste has been established by both animal and human clinical studies.<sup>30-33</sup>

We hypothesize that articular cartilage paste grafting is a viable cartilage repair technique that provides durable cartilage repair tissue with long-term improvement in function and diminishment of pain. This was a prospective, longitudinal, Institutional Review Board (IRB) approved, 2 to 12 year follow-up study to clinically and histologically evaluate the ability of articular cartilage paste grafting to surgically treat degenerative lesions in the knee joint. We specifically focused on chronic degenerative lesions and included knees with osteoarthritis to evaluate the ability of this technique to provide relief in this difficult patient population that is not currently addressed by other techniques.

## METHODS

### Subjects

This clinical and histologic study of an articular cartilage paste graft surgical treatment of patients with chronic Outerbridge grade IV lesions consisted of 145 patients, 2 of whom are deceased and 18 of whom were lost to follow-up (13.7%).<sup>34</sup> The remaining 125 patients underwent paste grafting between November 1991 and December 2002. There were 82 men

**TABLE 1.** *Inclusion and Exclusion Criteria*

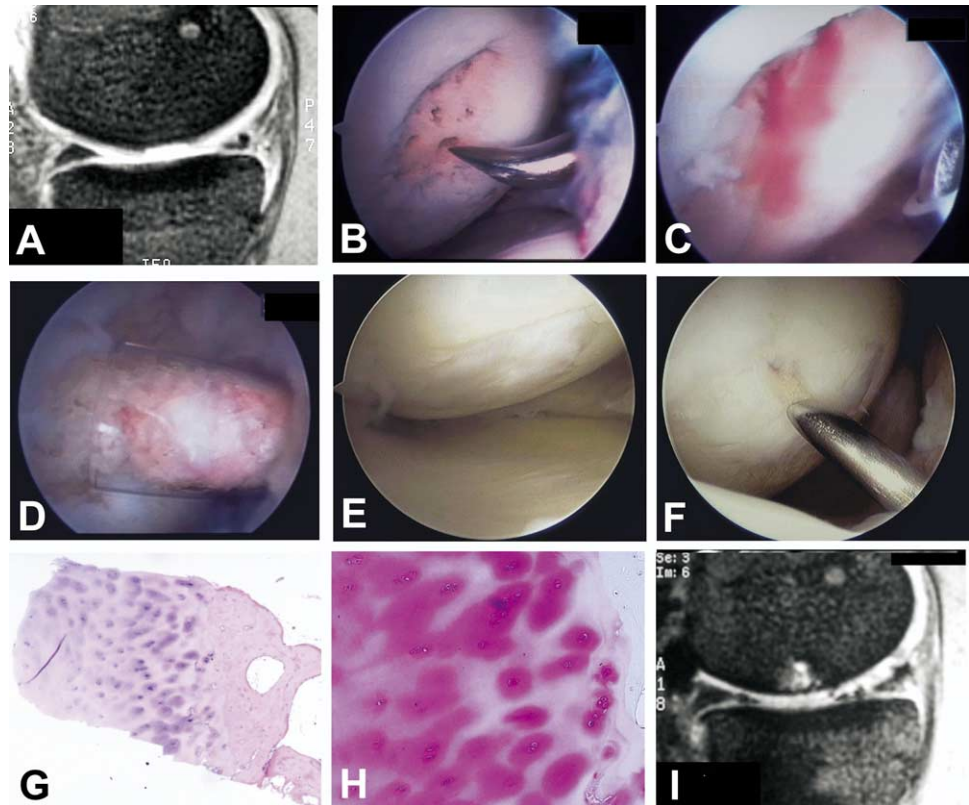
Inclusion Criteria	Exclusion Criteria
Confirmed full-thickness	Inflammatory arthrosis
Outerbridge grade IV	Severe malalignment (>7°)
chondral defects as	Significant uncorrected instability
indicated by exposed bone	Isolated patellar lesions
during previous surgery or	Far posterior lesions that could
the combination of	not be reached with available
radiography and MRI	grafting instrumentation
Active patients willing to	Acute focal chondral defects
participate in a	
postoperative rehabilitation	
program including 1 month	
of continuous passive	
motion	
Absence of severe	
malalignment (<7°)	
A stable or stabilized joint	
Not responsive to	
nonoperative care	

(65.6%) and 43 women (34.4%) with an average age of 46 years (range, 17 to 73 years). Average follow-up time was 51.5 months (range, 24 to 144 months). Patients were enrolled after IRB-approved informed consent according to the inclusion and exclusion criteria listed in Table 1.

### Chondral Lesions

All lesions were classified as Outerbridge grade IV lesions represented by erosion to subchondral bone (Fig 1).<sup>34</sup> Lesions grafted included 76 medial femoral condyles, 23 lateral femoral condyles, 24 trochlea, and 11 tibial plateaus. The average area grafted was 28.6 cm<sup>2</sup> (range, 2.4 to 140 cm<sup>2</sup>). Figure 2 is representative of the severity of defects often seen in this patient population. At arthroscopy, a full-thickness articular cartilage lesion was confirmed in the knee of each patient. Of 125 patients, 93 (74.4%) had undergone previous surgical procedures to the affected knee with a mean number of past surgeries of 1.7 (range, 1 to 7), including abrasion arthroplasties, microfractures, chondroplasties, and meniscectomies. Fifty-seven patients (46%) underwent concomitant procedures, including a meniscus allograft transplantation (21 patients, 37%), ACL reconstruction or repair (28 patients, 49%), or both (8 patients, 14%). Indications for paste grafting of previously failed procedures included a failure to respond to additional conservative treatment, and consistently high self-reported pain scores (average pain score of 1.82 on a 0 to 3 point scale, with 3 being severe pain); 75% of patients had

**FIGURE 1.** Preoperative, inter-operative, and postoperative images of paste grafting a full-thickness degenerative chondral lesion. (A) Preoperative MRI with full-thickness lesion of the medial femoral condyle. (B) Microfracture of the lesion with awl through subchondral bone. (C) Blood weeping through from marrow. (D) Intraoperative placement of the articular cartilage past graft. (E) Healed lesion 7 months postoperatively. (F) Healed defect biopsy taken with Jamshidi needle. (G) Histology specimen showing regenerate cartilage tissue (H&E, original magnification  $\times 1$ ). (H) Histology specimen showing mature chondrocytes (H&E, original magnification  $\times 10$ ). (I) MRI 15 months postoperatively with re-establishment of chondral surface.



failed previous surgical treatment for their cartilage lesions.

### Surgical Technique

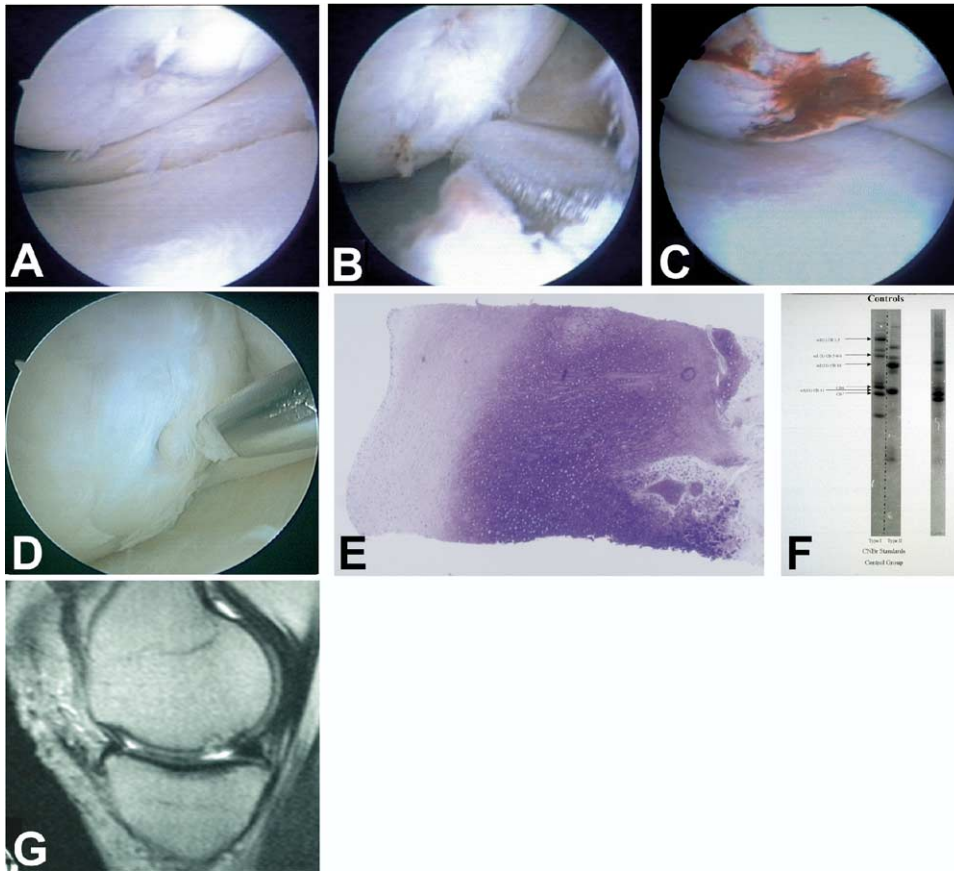
Osteochondral articular cartilage paste grafting was performed as an outpatient surgical procedure under local or general anesthesia. The surgical technique was previously reported by Stone and Walgenbach<sup>30,31</sup> as follows:

Damaged cartilage was shaved to remove fibrillated tissue. The lesion was then penetrated at multiple sites in the bed of the lesion with an arthroscopic awl until bleeding occurred (Fig 3A). Tissue for graft preparation was harvested from the margin of the intercondylar notch using an 8-mm trephine impacted into the margin of the articular cartilage and from the underlying cancellous bone to a depth of 1.5 cm (Fig 3B). The trephine was removed and the graft morselized manually in a graft impactor (DePuy, Warsaw, IN; Fig 3C). The paste created from the cancellous bone and articular cartilage was then impacted into the fractured bed of the chondral defect (Fig 3D). The impacting step was performed multiple times. No attempt was made to fill the

defect, only to cover it and impact paste graft into the penetrations in the bone. The paste graft material formed a grout of chondrocytes, matrix, and bone marrow in the interstices of the exposed bone. The paste graft was held in place for 1 to 2 minutes and then the instruments were removed, after which 50 mL of 0.25% bupivacaine with epinephrine and 1.0% lidocaine was injected into the joint and the patients were returned to the postoperative recovery room. If other arthroscopic procedures were to be performed, the impaction of the paste was the last step.

### Postoperative Rehabilitation

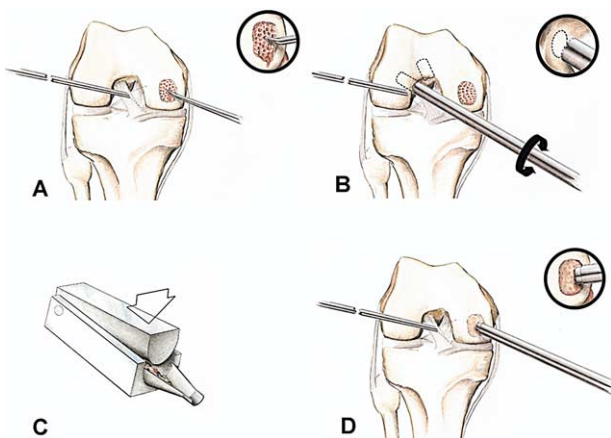
Postoperatively, all patients were requested to use a continuous passive motion machine for 6 hours a night for 4 weeks. Weight-bearing was permitted after 4 weeks, except for patients with trochlear lesions who were permitted immediate weight bearing in full extension locked in a brace. Patients underwent a defined rehabilitation program preoperatively and again on the first postoperative day (Appendix I).<sup>30</sup>



**FIGURE 2.** Preoperative, interoperative, and postoperative images of paste grafting of a degenerative chondral lesion. (A) Medial femoral condyle showing degenerative changes in a 32-year-old man. (B) Paste grafting of the femoral chondral lesion. (C) Fibrin clot formed after 5 minutes to hold paste graft in place. (D) Healed defect biopsy of regenerated cartilage tissue from the medial femoral condyle taken with a Jamshidi needle. (E) Histology specimen showing regenerated cartilage repair tissue 2 years status post paste grafting (toluidine blue, original magnification  $\times 1$ ). (F) Gel electrophoresis showing mixture of 80% type 1 and 20% type 2 collagen. (G) MRI 2 years after paste grafting showing regenerated femoral condylar surface.

### Follow-up Schedule

Approximately the first half of the patients were asked to undergo a second-look arthroscopy at a min-



**FIGURE 3.** (A) Morselizing the lesion to bleeding bone. (B) Harvesting of articular cartilage and cancellous bone from the intercondylar notch. (C) Manually crushing the graft into paste. (D) Impacting the paste graft into the morselized lesion. (Reprinted with permission.<sup>30</sup>)

imum of 1 year after paste grafting to assess the long-term histologic appearance of the regenerated tissue. All patients underwent clinical examinations by the senior author at months 1 and 3, and at years 1, 2, 5, 7, 10, and 12. Additionally, patients independently completed validated preoperative and postoperative evaluation forms: the Western Ontario and McMaster Universities Arthritis Index (WOMAC), International Knee Documentation Committee (IKDC), and Tegner modified pain and function forms. Magnetic resonance imaging (MRI) was not a requirement because, at the inception of this study in 1991, MRI was not as widely used as it is today. Radiographs frequently did not show the chondral lesions, and therefore were not a part of the outcome assessment.

### Histologic Methods

Tissue obtained from patients, who returned for a biopsy examination either voluntarily or because of arthrofibrosis, pain, or new injury, was harvested arthroscopically using a 13-gauge Jamshidi biopsy needle through the midpoint of the grafted lesion.<sup>33</sup> The

**TABLE 2.** *Histology Parameters and Observations.*

Category	Observation	Of 47 Regenerate Surfaces	Of 18 Equivocal Surfaces
Articular regenerate	Thickness estimate	2.11 mm (range, 0.3–5.24 mm)	2.30 mm (range, 0.31–4.69 mm)
	Hyaline cartilage	20	18
	Fibrocartilage + GAG	42	9
	Fibrocartilage – GAG	18	3
	Fibrous	10	3
	Tidemark	7	16
Subchondral region	Fibrosis	28	5
	Cartilage	36	9
	Woven bone	41	7
	Lamellar bone	38	13

NOTES. The numbers are greater than 65 because differing types of cartilage occur on each biopsy. Equivocal surfaces are those surfaces histologically indistinguishable from normal articular cartilage.

midpoint was determined by intraoperative comparison of the digital photograph of the original lesion with the healed area, as confirmed by 2 members of the surgical team at the time of the biopsy. All tissues were processed by the same histologist with hematoxylin and eosin, Safranin O/Fast Green, and toluidine blue stains. All slides were evaluated in a blinded format by an orthopaedic surgeon with an established publication record in orthopaedic pathology and independent of the primary investigator. The grading scale and definitions used for the blind evaluation are summarized in [Table 2](#).

Specimens were assessed for (1) tissue type(s), (2) presence of glycosaminoglycans (GAG), (3) depth (thickness) of presumed regenerate tissue, (4) presence of a tidemark, and (5) features of the subchondral region. All sections were observed by both bright field (BF) and polarized light microscopy (PLM). PLM defines anisotropic features that are specific differentiating features distinguishing articular cartilage from other hyaline-type cartilage.<sup>35,36</sup> PLM shows collagen fiber continuity across the interface in regenerate tissue, but not in normal articular cartilage. The interface between subchondral bone and overlying tissue was also assessed. The first group of patients ( $n = 13$ ) undergoing biopsy examination had a second specimen sent for collagen typing by gel electrophoresis and collagen labeling conducted in a blinded fashion.

### Statistical Methods

The nonparametric Wilcoxon signed-ranks test for repeated measures was used to compare preoperative and postoperative effects of surgery.<sup>37</sup> Additionally, a Wilcoxon rank-sum test for indepen-

dent groups, was used to test differences between genders on postoperative measures.<sup>37</sup> A Pearson correlation coefficient was used to determine a linear correlation between age and any of the postoperative measures thereby requiring statistical adjustments. A Pearson correlation coefficient was also used to determine a linear correlation between the months from surgery and postoperative pain and functioning scores, and therefore determine the long-term clinical outcomes of the articular cartilage graft technique. A 1-way analysis of variance was conducted to determine if the pain and functioning scores differed significantly based on the histologic appearance of the biopsies. The statistical power, with a 2-sided  $\alpha = 0.05$ , an effect size  $\delta = 1.05$ , and  $n = 125$ , was over 0.90.

## RESULTS

### Clinical Results

Statistically significant ( $P = .001$ ) improvement from all preoperative to postoperative validated self-reported measures on the WOMAC were noted ([Table 3](#)). The largest mean improvement occurred in pain, ascending stairs, and descending stairs scores. The non-parametric Wilcoxon rank-sum evaluated the hypothesis that the postoperative means would be significantly lower than the preoperative means, thereby indicating improvement. Improvements were independent of gender, age, months from surgery, the number of previous surgical interventions, concurrent surgeries, or type of concurrent surgery.

From 2 to 5 years, 82% of patients reported improved pain relief, 10.1% did not improve, and 7.9% worsened. Only 1 additional patient worsened from 5 to 12 years

**TABLE 3.** *Self-assessed Preoperative and Postoperative Pain Scores of 125 Patients*

Variable	Preop	Postop	P Value
<b>Pain*</b>			
Mean	1.82	0.87	.001
Standard deviation	0.76	0.75	
<b>Functioning†</b>			
Mean	1.62	0.69	.001
Standard deviation	0.66	0.67	
<b>Stiffness</b>			
Mean	1.76	1.08	.001
Standard deviation	0.76	0.86	
<b>Ascending stairs</b>			
Mean	2.00	0.88	.001
Standard deviation	0.92	0.81	
<b>Descending stairs</b>			
Mean	2.05	1.02	.001
Standard deviation	0.83	0.99	

\*Based on the WOMAC questionnaire, where 0 = absence of difficulty and 3 = severe difficulty.

†Based on the Tegner functioning questionnaire, where 0 = absence of difficulty and 3 = severe difficulty.

after surgery. Five to 12 years from surgery, 94% claimed improved postoperative pain, 1 patient (3%) reported no improvement in pain, and 1 (3%) reported worse pain. This is consistent with the finding of no significant correlation of pain and functioning measures with months from surgery (Tables 4 and 5). Failure analysis of functioning scores resulted in the same trend over the first 5 years, with 10 of 13 patients (77%) who reported worse functioning 2 to 5 years from surgery. Only 3 patients (8.3%) reported worse functioning 5 to 12 years from surgery (Table 5).

Overall, 82% of subjective measures were improved from 2 to 12 years, 9.6% remained the same, and 8.4% worsened. Eighty-one percent of decreased scores were reported 2 to 5 years from surgery.

**Histologic Results**

Each biopsy specimen had regional histologic variation. Forty-two of 65 biopsies (64.6%) showed by

**TABLE 4.** *Differences in Preoperative and Postoperative Pain Scores Based on Years From Surgery*

Years From Surgery	Improved Pain	Same Pain	Worse Pain	Total
2-3	35 (83.3%)	5 (12.0%)	2 (4.7%)	42 (100%)
3-4	15 (75.0%)	2 (10.0%)	3 (15.0%)	20 (100%)
4-5	23 (85.2%)	2 (7.4%)	2 (7.4%)	27 (100%)
5-6	11 (91.7%)	1 (8.3%)	0 (0.0%)	12 (100%)
6-12	23 (95.8%)	0 (0.0%)	1 (4.2%)	24 (100%)
Total	107 (85.6%)	10 (8.0%)	8 (6.4%)	125 (100%)

**TABLE 5.** *Differences in Preoperative and Postoperative Functioning Scores Based on Years From Surgery*

Years From Surgery	Improved Function	Same Function	Worse Function	Total
2-3	32 (76.2%)	6 (14.3%)	4 (9.5%)	42 (100%)
3-4	16 (80%)	2 (10.0%)	2 (10.0%)	20 (100%)
4-5	21 (77.8%)	2 (7.4%)	4 (14.8%)	27 (100%)
5-6	9 (75.0%)	2 (16.7%)	1 (8.3%)	12 (100%)
6-12	20 (83.4%)	2 (8.3%)	2 (8.3%)	24 (100%)
Total	98 (78.4%)	14 (11.2%)	13 (10.4%)	125 (100%)

histologic criteria strong and consistent evidence of articular cartilage surface regeneration. The thickness of the regenerate tissue averaged 2.29 mm (range, 0.3 to 5.24 mm). Fibrocartilage without GAG was present in all or part of 18 of the regenerate tissue biopsy specimens (38%). Fibrous tissue made up all or part of regenerate tissue in 10 biopsies (15%). Most interesting was the restoration or persistence of the tidemark in 23 of 65 patients (35%) in this group of Outerbridge grade IV lesions. Histologic results are summarized in Table 2.

Eighteen of sixty-five biopsy specimens (27.6%) had areas of hyaline cartilage in the biopsy indistinguishable from normal cartilage, of which 16 biopsies with tidemarks were present (89%). The articular cartilage thickness averaged 2.3 mm (range, 0.3 to 4.69 mm) in this hyaline-regenerate subject group. All 18 patients showed encroachment by bony, vascular, and/or fibrous subchondral tissue into the overlying cartilage approaching or crossing the tidemark.

One specimen showed macrophage inflammatory cells surrounding a fragment of defibrillating cartilage, revealing acellular cartilage debris within the bone marrow. Another specimen showed a partially eburnated surface with a tag of regenerate tissue that appeared to be contiguous with the surface (counted as new). The same specimen showed nests of proliferating cartilage within marrow spaces and a unilateral layer of hyaline cartilage that appeared to be deep to a tidemark.

Histologic data revealed that those with regenerate cartilage did have better pain scores than those with fibrocartilage without GAG, but the difference was not significant ( $P = .16$ ). Collagen typing and gel electrophoresis revealed a mixture of type I and II collagen in all biopsies. This is consistent with a mixture of cartilage repair tissue and histochemically abnormal articular cartilage and has high correlation with the observed regional variation as seen histologically in the regenerate tissue.

thoscopically. Although no instability was found on arthroscopic probing, biopsies at the regenerated articular surface and the native surface interface have not been obtained and the fusion between these areas cannot be commented on in this human clinical setting.

## DISCUSSION

The principal findings of the present study support paste grafting as a viable technique for cartilage regeneration through both clinical and histologic assessments. Paste grafting appears to stimulate cartilage repair first by creating a fresh fracture bed in an area of degenerate cartilage and bone, and second by providing an environment for the mesenchymal cells of bone marrow to interact with the combination of articular cartilage matrix and live chondrocytes.<sup>38</sup> The primary evidence for the repair process lies in the regeneration of cartilage and defect fill. Secondary indications for repair include restoration of the tidemark and production of new GAGs.

Marrow stimulation by debridement and microfracture is widely used to treat local chondral defects by penetrating the subchondral bone to initiate a healing response through a fibrin clot formation. Microfracture, first described by Steadman et al. in 1997,<sup>23</sup> can be performed arthroscopically and is associated with low morbidity. Although marrow cells are released to initiate a strong healing response, microfracture generally results in biomechanically inferior fibrin or a mixture of hyaline and fibrocartilage regenerate tissue. Most importantly, microfracture is only indicated for isolated chondral defects and not for arthrosis. Eleven percent of patients treated with articular cartilage paste grafting during the period of this study had previously undergone microfracture and were revised with this paste grafting technique. These examples of failed microfracture salvaged with paste grafting have given us confidence that this more aggressive fracturing augmented with matrix and chondrocytes has clinical validity.

Autologous chondrocyte implantation (ACI), initially reported by Grande et al.<sup>9</sup> and then more recently by Brittberg et al.,<sup>8</sup> requires an initial arthroscopic chondrocyte harvest surgery followed by an open arthrotomy, sewing of a perichondral flap, resorbable membrane or matrix, and then injection of cultured chondrocytes beneath the flap. This 2-step procedure can be quite costly, is surgically challenging, and is indicated for isolated chondral lesions in

nonarthritic knees.<sup>8,9</sup> Recent controlled studies comparing clinical and histologic results of ACI with those of osteochondral cylinder transplantation by Horas et al.,<sup>25</sup> and ACI with microfracture by Knutsen et al.<sup>26</sup> found no statistically significant difference in outcomes of ACI versus either technique. Because of the lack of indicated techniques at the commencement of this study in 1991 in the setting of multiple lesions, severe arthrosis, and previously failed chondral resurfacing, we did not believe we could conduct a comparative controlled or double-blinded study.

This study evaluated both tissue quality and clinical outcome in chronic degenerative osteochondral lesions. Some patients clearly have the ability to develop near normal appearing new cartilage in chronically worn areas that is durable for up to 12 years. What differentiates these patients from those who develop pure fibrocartilage has yet to be determined. Surprisingly, outcome was independent of the type of repair tissue. As yet, we are unable to quantify either continuous passive motion use, postoperative program compliance, amount of cartilage versus cancellous bone in the paste, age, or activity level to histologic or clinical outcome. Only 3 of 125 patients in 12 years have required repeat grafting. Eighteen of 125 (14.4%) patients are considered failures; 10 required arthroplasty and 8 claimed worse postoperative pain than preoperative pain.

Paste grafting as described in this study has the benefits that it is relatively easy because the technique can be performed under local anesthesia on an outpatient basis and it is cost-effective. However, the technique can be challenging for posterior femoral or posterior tibial lesions in that they are hard to reach and graft arthroscopically. Similarly, no patellar lesions have been grafted because of the lack of instrumentation and the authors' wariness of patellar lesions.

The IKDC, WOMAC, and Tegner questionnaires revealed highly significant self-reported improvement in pain, functioning, and stiffness. Improvement was regardless of age, gender, or years from surgery (Tables 3-5). Furthermore, almost all of those patients 6 to 12 years from surgery remain improved. Of the patients reporting pain, 7 reported before 5 years and 1 in the 5 to 12 year interval, implying that if patients make it to 5 years without increased pain, they do quite well for up to 12 years. Therefore, the durability of the regenerated tissue in the setting of arthrosis is quite good. This procedure offers significant long-lasting pain relief, restored functioning, and the pos-

sibility of repair tissue regeneration for patients with chondral lesions in degenerative knees.

### Study Limitations and Technique Considerations

The limitations in this study include a histology assessment that is subject to possible sampling error as a result of location or orientation of the biopsy specimens and the inability to obtain interface data between the graft and host without multiple biopsies. Additionally, at the initiation of the study, there was no validated questionnaire for the assessment of treated cartilage lesions alone. Preoperative and postoperative MRI assessments were not routinely obtained at the inception of this study and were not a requirement during IRB approval of this study.

After placement of the graft, clot formed from subchondral marrow and blood access holds the paste in position.<sup>30-33</sup> Although some of the graft can fall off into the joint, no harm appears to have been caused at the donor site and no complications, such as symptomatic loose bodies, have occurred during the course of this study as a result of this treatment. A covering or additive adhesive may help to improve this pasting procedure.

We acknowledge that the data presented here will be strengthened by a prospective blinded controlled study in comparison with debridement alone or microfracture alone. When the study was designed, we were not aware of any other methods reported for the treatment of arthritic lesions or for when the patients had previously failed standard treatment. Microfracture or autologous chondrocyte transfer are still not indicated in arthrosis.

The significance of this study lies in more than just the validation of a new method, but also in the biology of lesion healing, and the improved clinical outcomes possible for patients with degenerative chondral lesions who are not indicated for most treatments short of joint arthroplasty. The realization that, while we cannot make normal cartilage, repair tissue may be sufficient for many patients to "buy time," await newer cartilage regeneration procedures, and ultimately delay joint arthroplasty.

### CONCLUSIONS

This study was designed to evaluate both tissue quality and clinical outcomes for a novel, cartilage repair technique for degenerative chondral lesions. Significant long-term pain relief and restored functioning was observed in this patient population. The

regenerated repair tissue was very durable for 2 to 12 years for most patients. Both those knees that regenerated areas of more normal appearing articular cartilage and those with a larger component of fibrocartilage obtained pain relief and restored functioning. The relief obtained by paste grafting grade IV lesions is independent of age, gender, or months from previous surgery, and should be considered as an appropriate primary and salvage cartilage repair technique.

**Acknowledgment:** Martin Hill, Ph.D., as senior biostatistician for The Stone Research Foundation, contributed to the collection and statistical analysis of the data in this study. We thank Sharon Bobrow for providing editorial coordination and support.

### REFERENCES

1. Buckwalter J, Lohmander S. Operative treatment of osteoarthritis: Current practice and future development. *J Bone Joint Surg* 1994;76:1405-1418.
2. Buckwalter JA, Mankin HJ. Articular cartilage: Degeneration and osteoarthritis, repair, regeneration, and transplantation. *J Bone Joint Surg Am* 1997;79:612-632.
3. Aston J, Bentley G. Repair of articular surfaces by allografts of articular and growth-plate cartilage. *J Bone Joint Surg Br* 1986;68:29-35.
4. Bentley G, Greer R. Homotransplantation of isolated epiphyseal and articular cartilage chondrocytes into joint surfaces of rabbits. *Nature* 1971;230:385-388.
5. Blevins F, Steadman R, Rodrigo J, et al. Treatment of articular cartilage defects in athletes: An analysis of functional outcome and lesion appearance. *Orthopaedics* 1998;21:761-768.
6. Bobic V. Arthroscopic osteochondral autograft transplantation in anterior cruciate ligament reconstruction: A preliminary study. *Knee Surg Sports Traumatol Arthrosc* 1996;3:262-264.
7. Brittberg M, Faxen E, Peterson L. Carbon fiber scaffolds in the treatment of early knee osteoarthritis. *Clin Orthop* 1994;307:155-164.
8. Brittberg M, Lindahl A, Nilsson A, et al. Treatment of deep cartilage defects in the knee with autologous chondrocyte transplantation. *N Engl J Med* 1994;331:889-895.
9. Grande D, Pitman M, Peterson L, et al. The repair of experimentally produced defects in rabbit articular cartilage by autologous chondrocyte transplantation. *J Orthop Res* 1989;7:208-218.
10. Guilak F, Ratcliff A, Lane N, et al. Mechanical and biochemical changes in the superficial zone of articular cartilage in canine experimental osteoarthritis. *J Orthop Res* 1994;12:474-484.
11. Hangody L, Kish G, Karpati Z, et al. Mosaicplasty for the treatment of articular cartilage defects: Application in clinical practice. *Orthopaedics* 1998;21:751-756.
12. Hendrickson D, Nixon A, Grande D, et al. Chondrocyte-fibrin matrix transplant for resurfacing extensive cartilage defects. *J Orthop Res* 1994;12:485-497.
13. Homminga G, Bulstra S, Bouwmeester P, et al. Perichondrial grafting for cartilage lesions of the knee. *J Bone Joint Surg Br* 1990;72:1003-1007.
14. Hunziker E, Rosenberg R. Induction of repair of partial thickness articular cartilage lesions by timed-release of TGF-Beta. *Trans Orthop Res Soc* 1994;19:236.
15. Itay S, Abramovici A, Nevo Z. Use of cultured embryonal



- chick epiphyseal chondrocytes as grafts for defects in chick articular cartilage. *Clin Orthop* 1987;220:284-303.
16. Mankin H, Buckwalter J. Restoring the osteoarthritic joint. *J Bone Joint Surg Am* 1996;78:1-2.
  17. Minas T, Nehrer S. Current concepts in the treatment of articular cartilage defects. *Orthopaedics* 1997;20:525-538.
  18. Muckle D, Minns R. Biological response to woven carbon fiber pads in the knee: A clinical and experimental study. *J Bone Joint Surg Br* 1990;72:60-62.
  19. Nixon A, Sarm A, Lust G, et al. Temporal matrix synthesis and histologic features of a chondrocyte-laden porous collagen cartilage analogue. *Am J Vet Res* 1993;54:349-356.
  20. Noguchi T, Oka M, Fujino M, et al. Repair of osteochondral defects with grafts of cultured chondrocytes: Comparison of allografts and isografts. *Clin Orthop* 1994;302:251-258.
  21. Robinson D, Halperin N, Nevo Z. Regenerating hyaline cartilage in articular defects of old chickens using implants of embryonal chick chondrocytes embedded in a new natural delivery substance. *Calcif Tissue Int* 1990;46:246-253.
  22. Seradge H, Kutz J, Kleinert H, et al. Perichondrial resurfacing arthroplasty in the hand. *J Hand Surg [Am]* 1994;9:880-886.
  23. Steadman JR, Rodkey WG, Singleton SB, et al. Microfracture technique for full-thickness chondral defects: Techniques and clinical results. *Oper Tech Orthop* 1997;7:300-304.
  24. Bentley G, Biant LC, Carrington RW, Akmal M, Goldberg A, Williams AM, Skinner JA, Pringle J. A prospective, randomised comparison of autologous chondrocyte implantation versus mosaicplasty for osteochondral defects in the knee. *J Bone Joint Surg Br* 2003;85:223-230.
  25. Horas U, Pelinkovic D, Herr G, Aigner T, Schnettler R. Autologous chondrocyte implantation and osteochondral cylinder transplantation in cartilage repair of the knee joint. A prospective, comparative trial. *J Bone Joint Surg Am* 2003;85:185-192.
  26. Knutsen G, Engebretsen L, Ludvigsen TC, et al. Autologous chondrocyte implantation compared with microfracture in the knee. A randomized trial. *J Bone Joint Surg Am* 2004;86:455-464.
  27. Alford JW, Cole BJ. Cartilage restoration, part 1: Basic science, historical perspective, patient evaluation, and treatment options. *Am J Sports Med* 2005;33:295-306.
  28. Bert J. Abrasion arthroplasty. *Oper Tech Orthop* 1997;7:294-299.
  29. Wirth, CJ Rudert, M. Techniques of cartilage growth enhancement: A review of the literature. *Arthroscopy* 1996;12:300-308.
  30. Stone KR, Walgenbach AW. Surgical technique for articular cartilage transplantation to full thickness cartilage defects in the knee joint. *Oper Tech Orthop* 1997;7:305-311.
  31. Stone KR, Walgenbach A. Articular cartilage paste grafting: Surgical technique and results. *Sports Traumatol Rel Res* 1998;20:1-9.
  32. Mahadev A, Mahara DP, Chang P, et al. Autogenous osteochondral morselised grafts for full thickness osteochondral defects in the knee joints of pigs. *Singapore Med J* 2001;42:410-416.
  33. Jaroszewski J, Kruczynski J, Piontek T, Trzeciak T, Kaszuba B, Lubiowski P. Value of autologous transplantation of osteochondral paste in reconstruction of experimental cartilage defects. Part II. Microscopic analysis of integration with surrounding cartilage, structural integrity and subchondral bone reconstruction in repair tissue. *Chir Narzadow Ruchu Ortop Pol* 2003;68:335-340.
  34. Outerbridge RE. The etiology of chondromalacia patellae. *J Bone Joint Surg Br* 1961;43:752-757.
  35. Poole CA. Articular cartilage chondrons: Form, function and failure. *J Anat* 1997;191:1-13.
  36. Speer DP, Dhanres L. Collagenous architecture of articular cartilage: Correlation of scanning electron microscopy and polarized light microscopy. *Clin Orthop* 1979;139:267-275.
  37. Fisher LD, van Belle G. *Biostatistics: A methodology for the health sciences*. New York: Wiley Interscience, 1993;310-315.
  38. Mithoefer K, Williams RJ III, Warren RF, et al. The microfracture technique for the treatment of articular cartilage lesions in the knee. *J Bone Joint Surg Am* 2005;87:1911-1920.